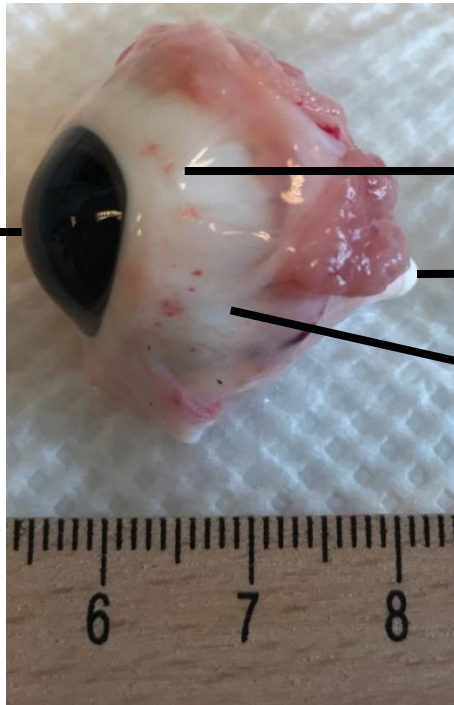


A

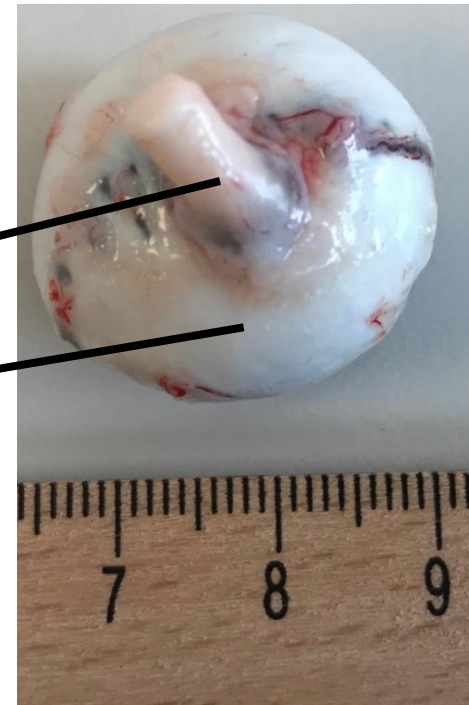
Cornea



Sclera

Optic nerve

Eye globe

B**C**

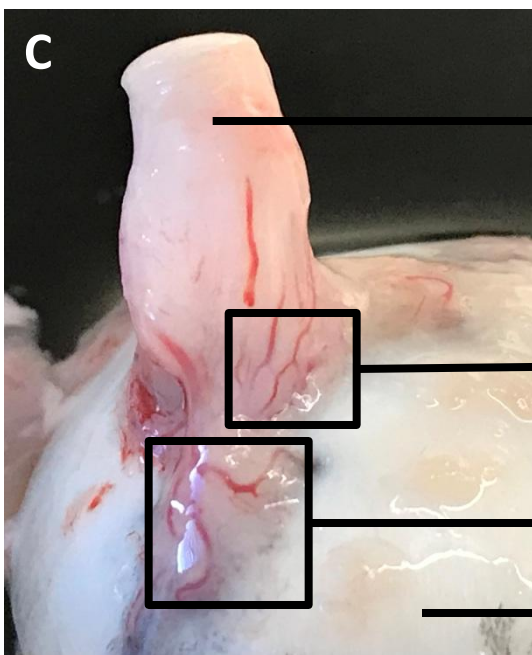
Optic nerve

sPCA with connective tissue

Paraoptic sPCA

Distal sPCA

Eye globe (Bulbus oculi)

**D**